

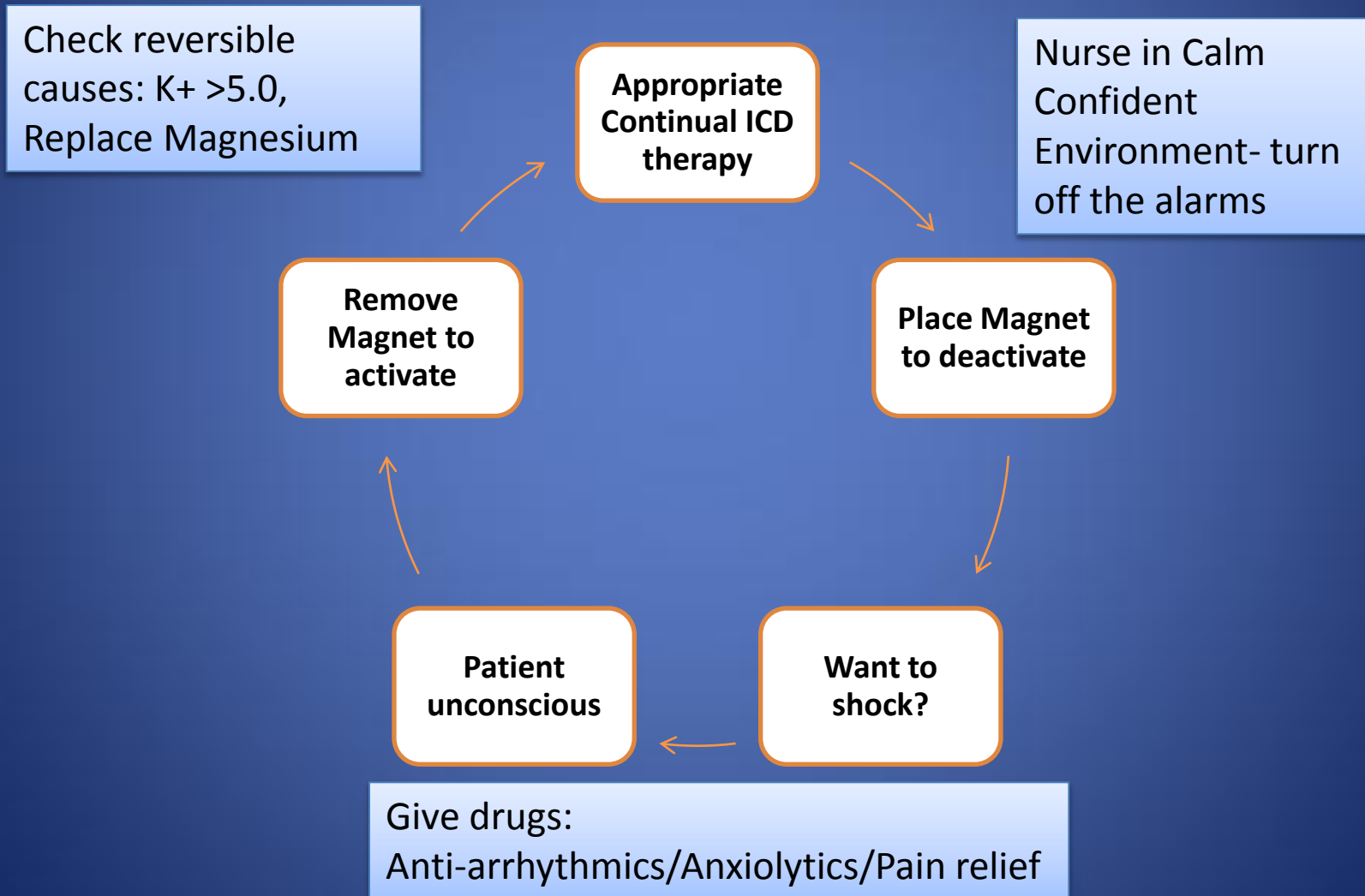
Internal Cardiac Defibrillators

The need to knows and dos

Dr TJ Pegg MBChB PhD

(who sucessfully blew up a
pacemaker during a cardiac arrest)

Standard cardiac arrest with an ICD and Magnet



Clinical Scenarios 1

- 55 year old man with Ischaemic Cardiomyopathy
- Primary prevention device
- Nil previous therapy
- Non specific flu like illness for 3 days
- Increasing SOB
- Presents with x 3 painful shocks
- No LOC

Clinical Scenario 2

- 67 year old man
- ICD implanted 20 years ago for primary prevention
- Moved from Australia- ?follow up in Nelson
- Presents with chest pain
- Collapses in ob1

Clinical Scenario 3

- 62 year old man
- Known Cardiac Sarcoid, EF 60%
- Recent ICD inserted 3/52 ago for VT
- Medications Metoprolol 95mg od
- X5 painful shocks this morning

Clinical Scenario 4

- 58 year old lady with St Judes ICD Riata Lead
- Long QT syndrome (Type 2)
- X1 DC shock during sexual intercourse
- X 3 DC shock at home
- Sinus rhythm on monitor

Clinical Scenario 5

- 63 year old man
- Primary prevention ICD inserted for ICM
- EF 25%
- Feeling unwell for 6 hours
- Dizzy light headed

Clinical Scenario 6

- 54 year old Chilean man
- Out Hospital Cardiac Arrest 2011
- ?Long QT syndrome
- Secondary Prevention ICD inserted
- Sitting exam in Nelson
- Palpitations commenced during exam
- X 2 Shock