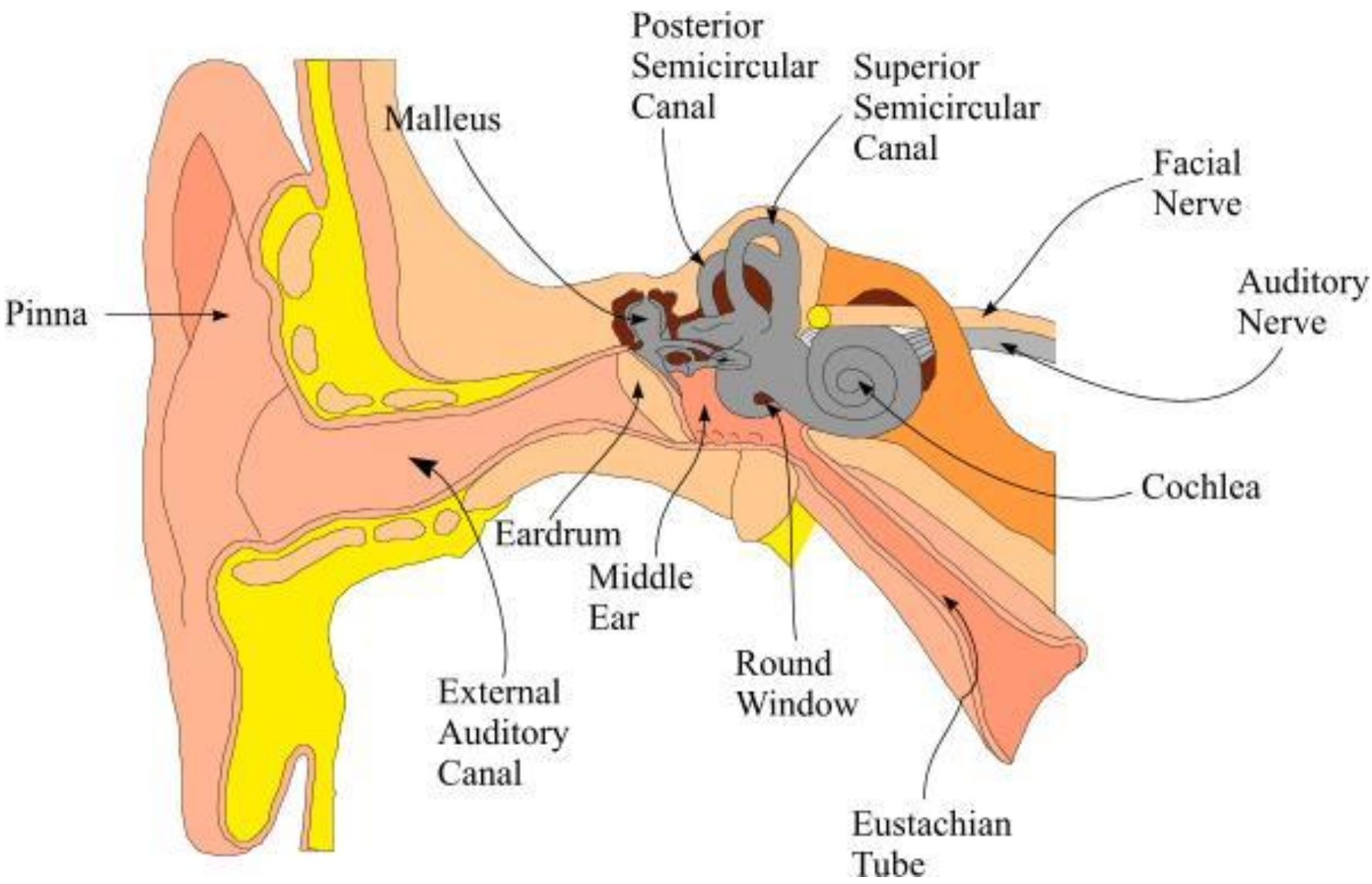
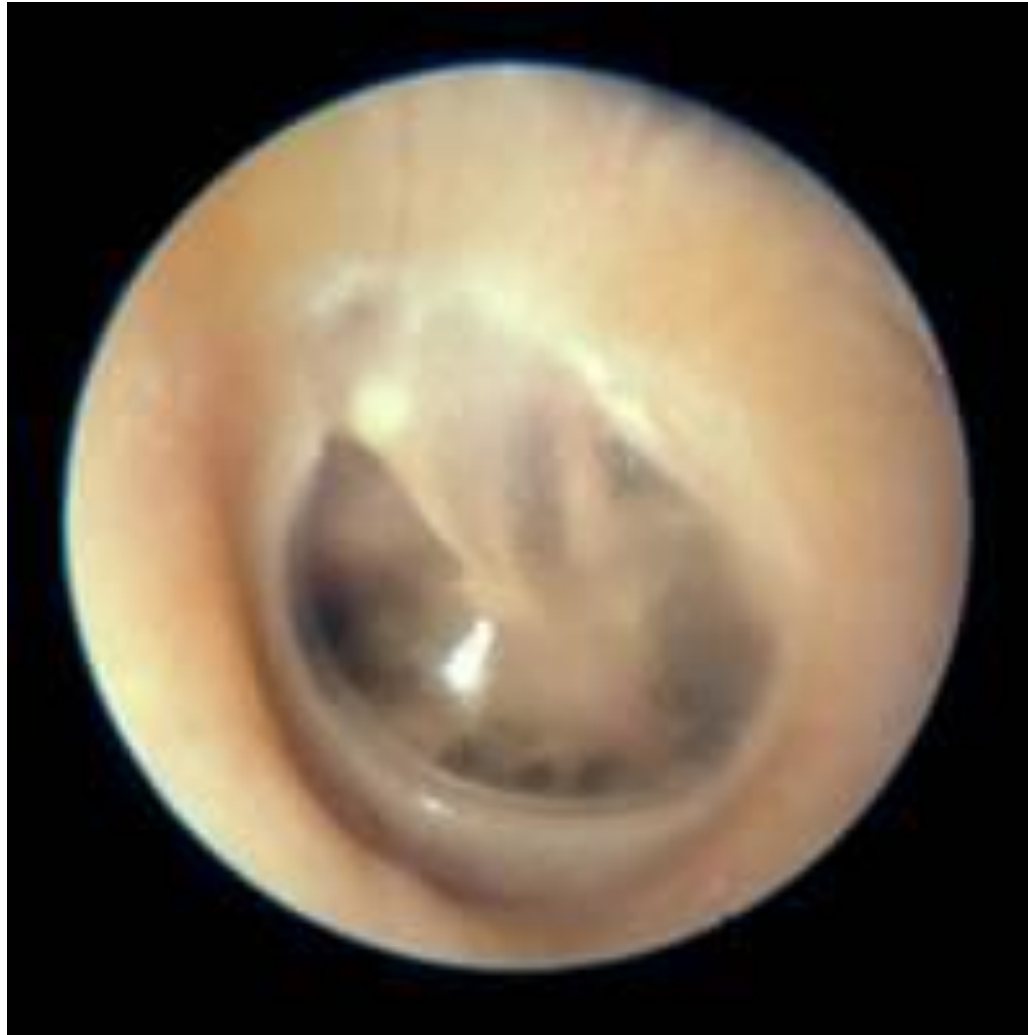

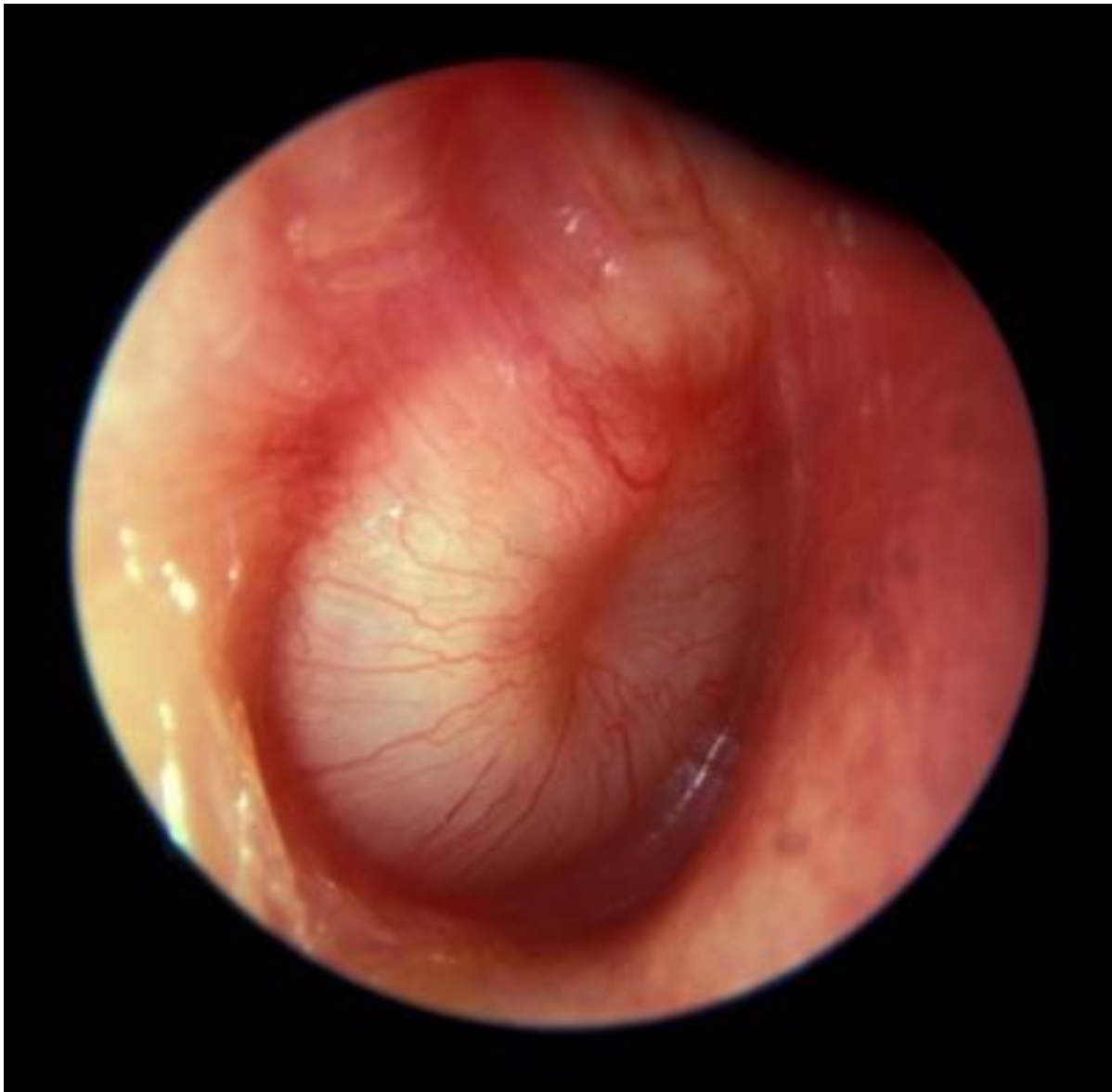The middle ear in pictures

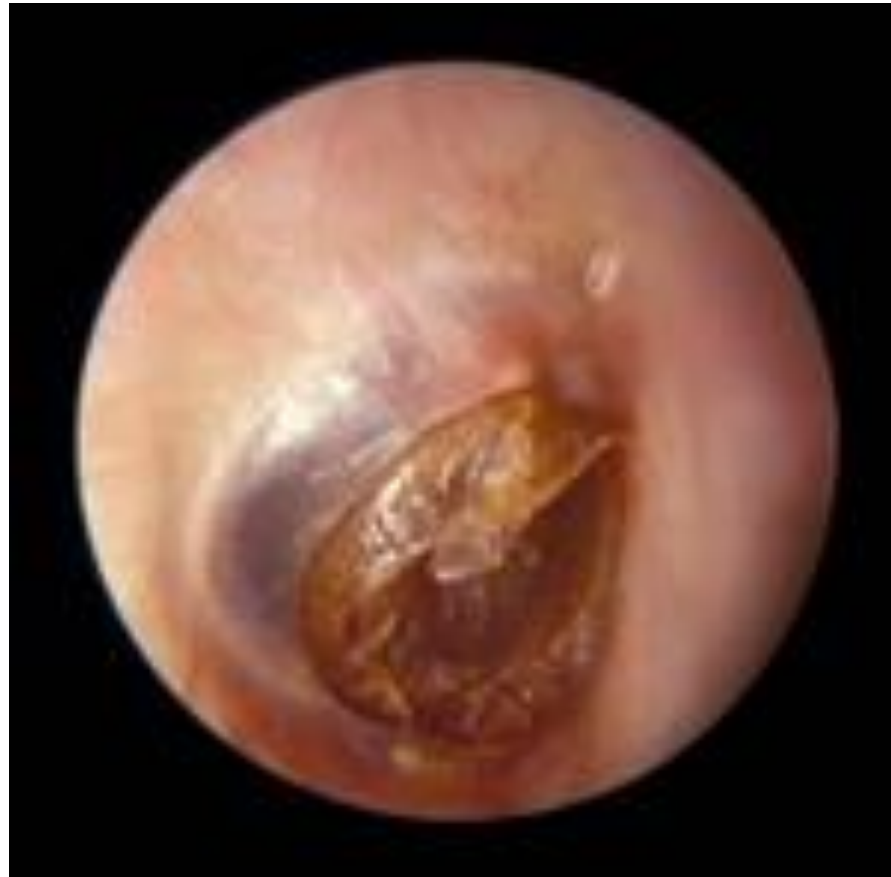Paul Phibbs

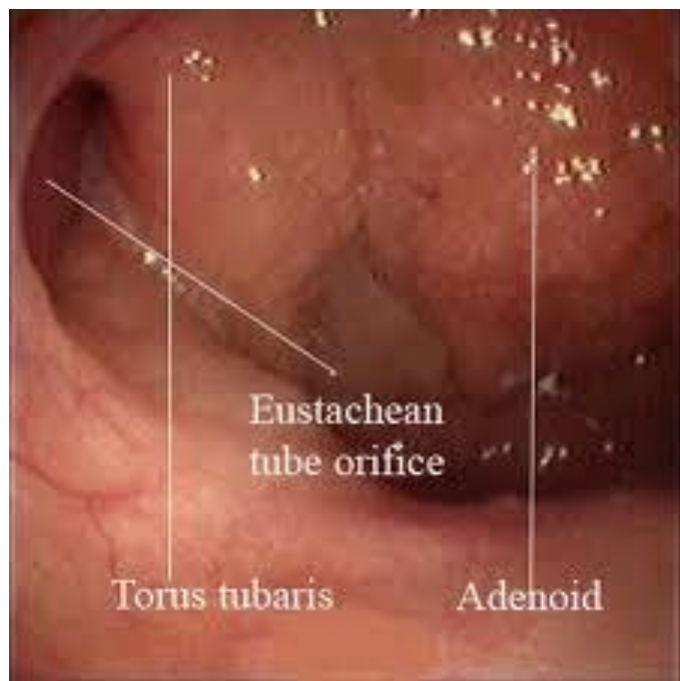Dept of Otolaryngology

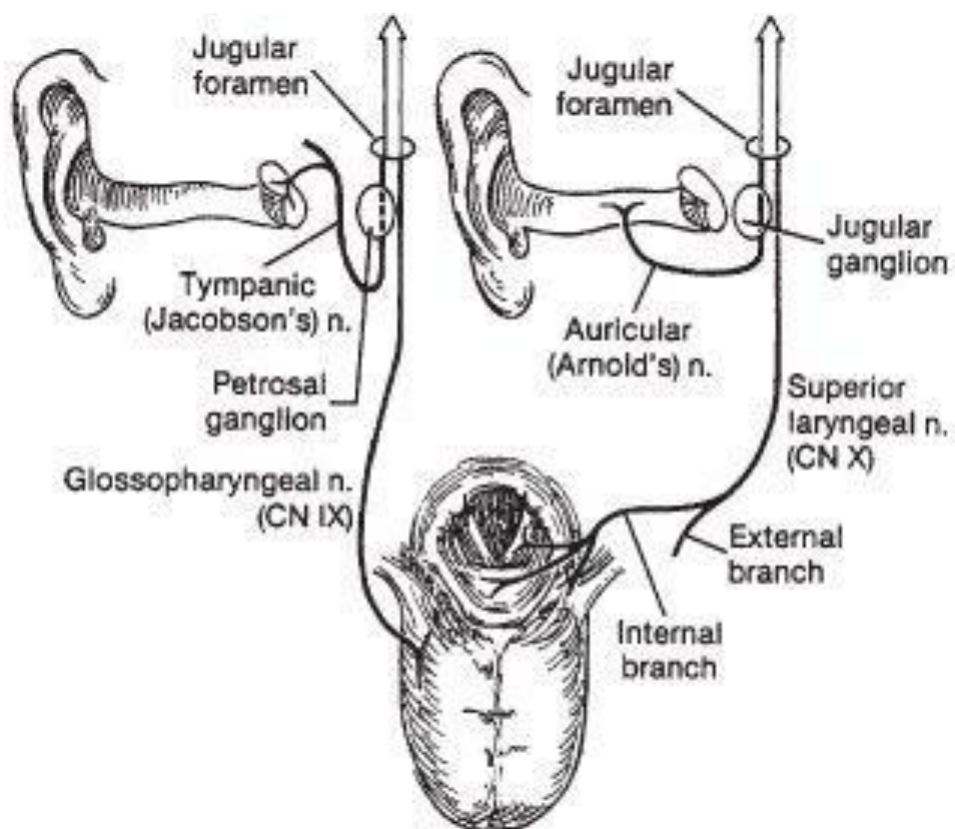


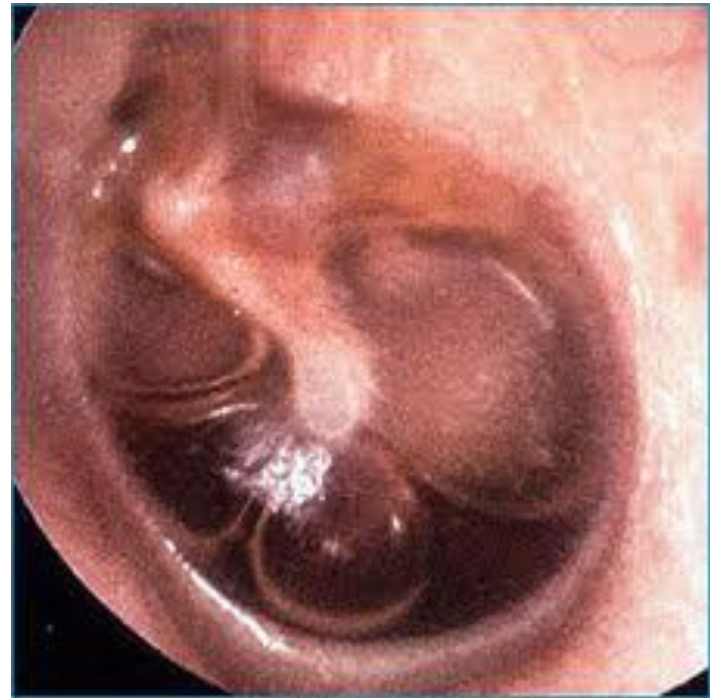
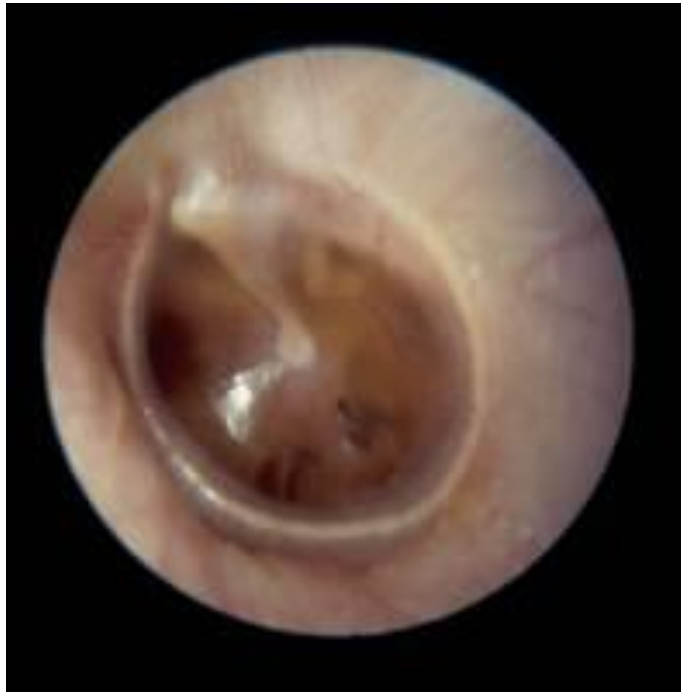
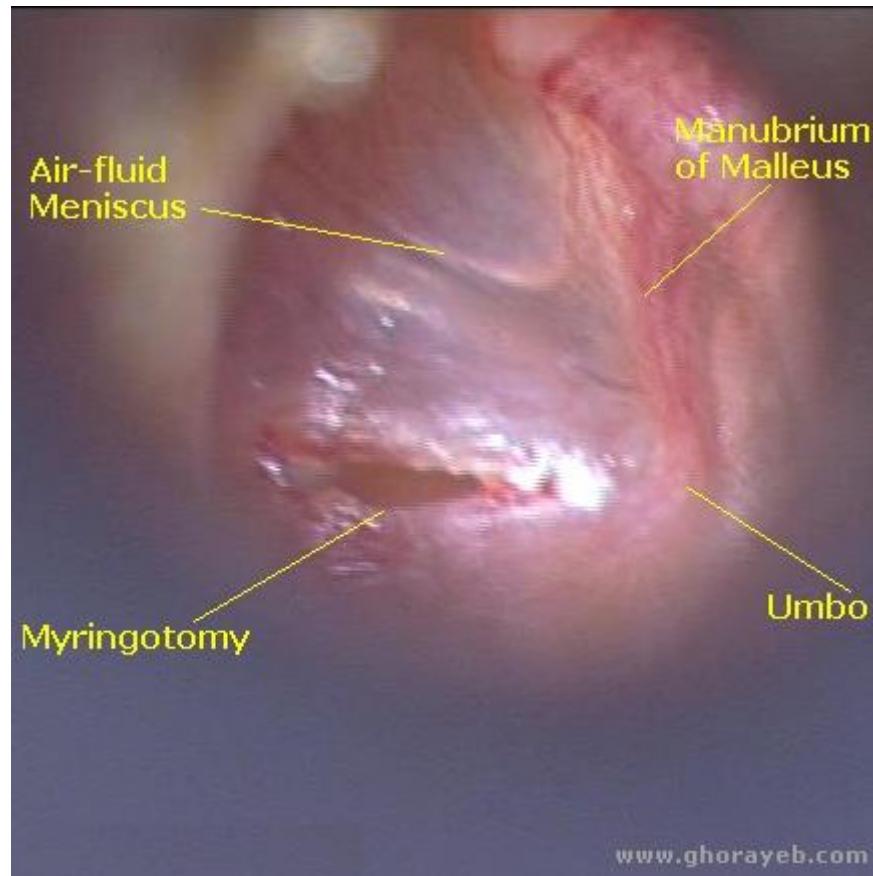




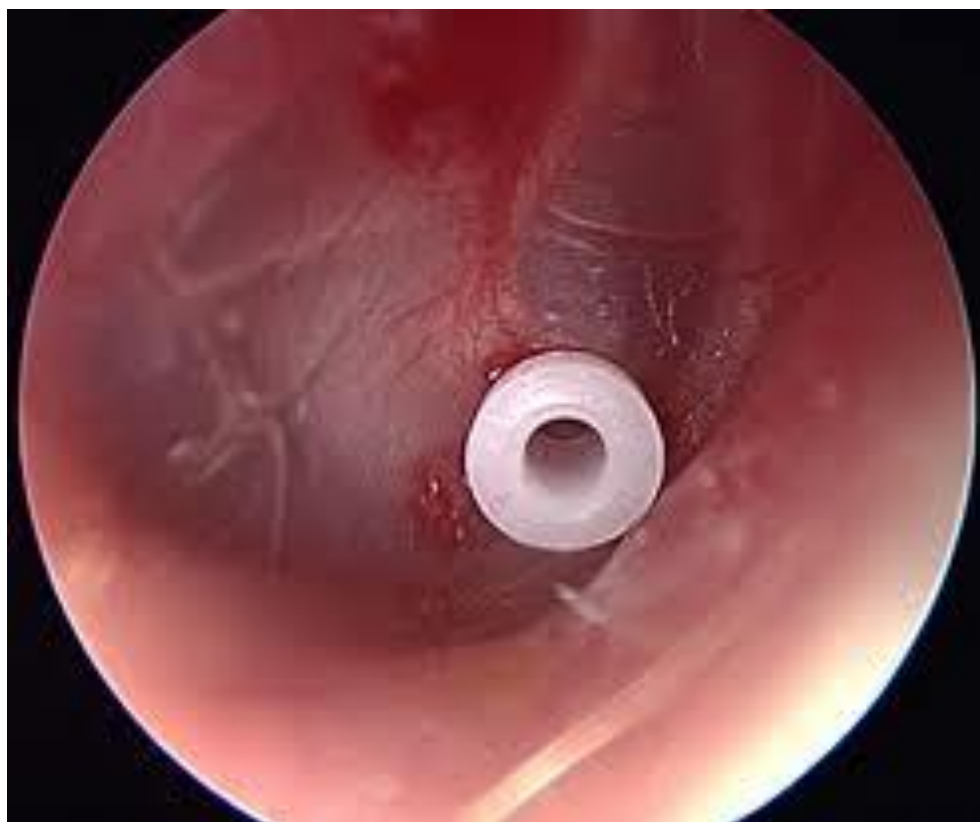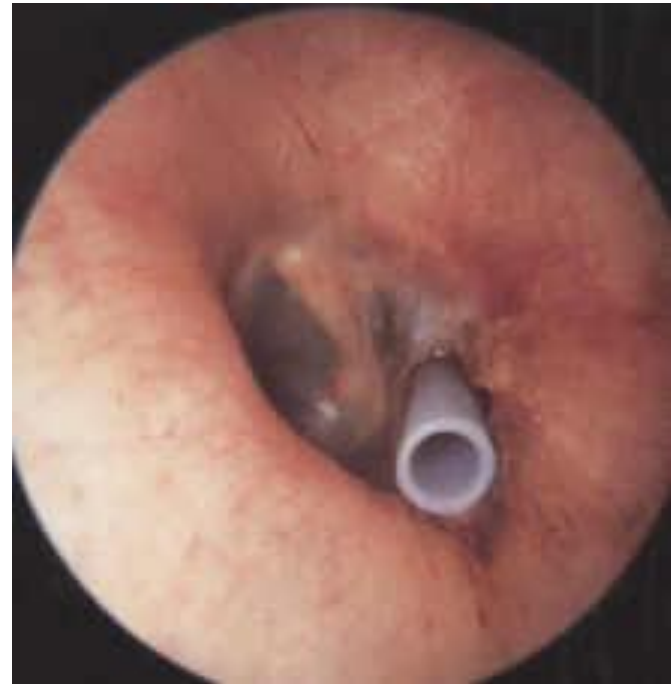





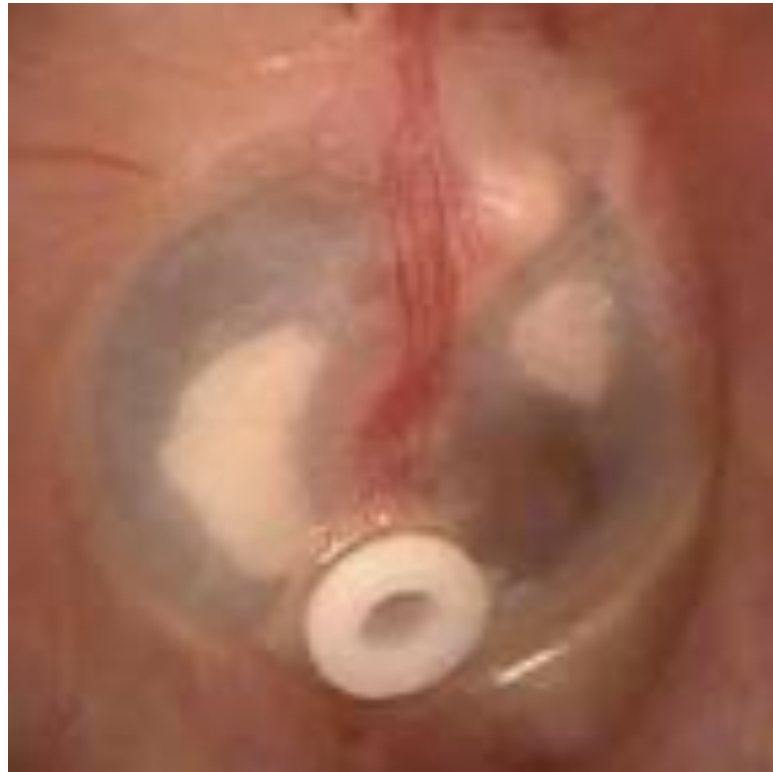


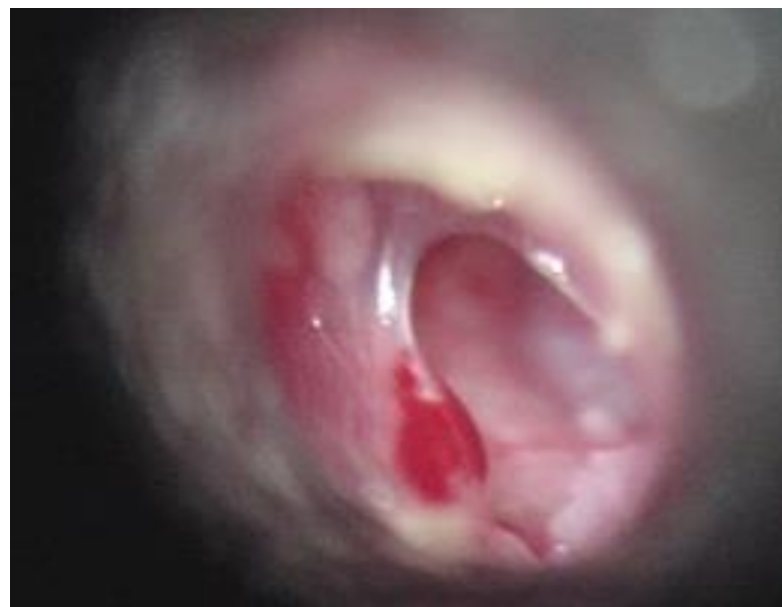
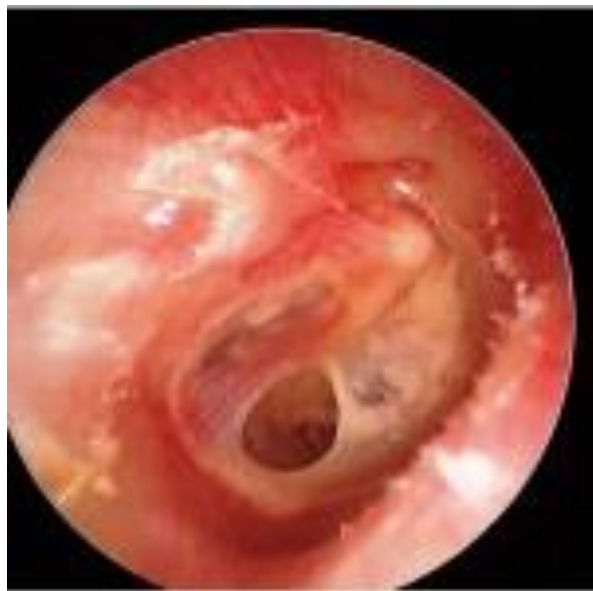






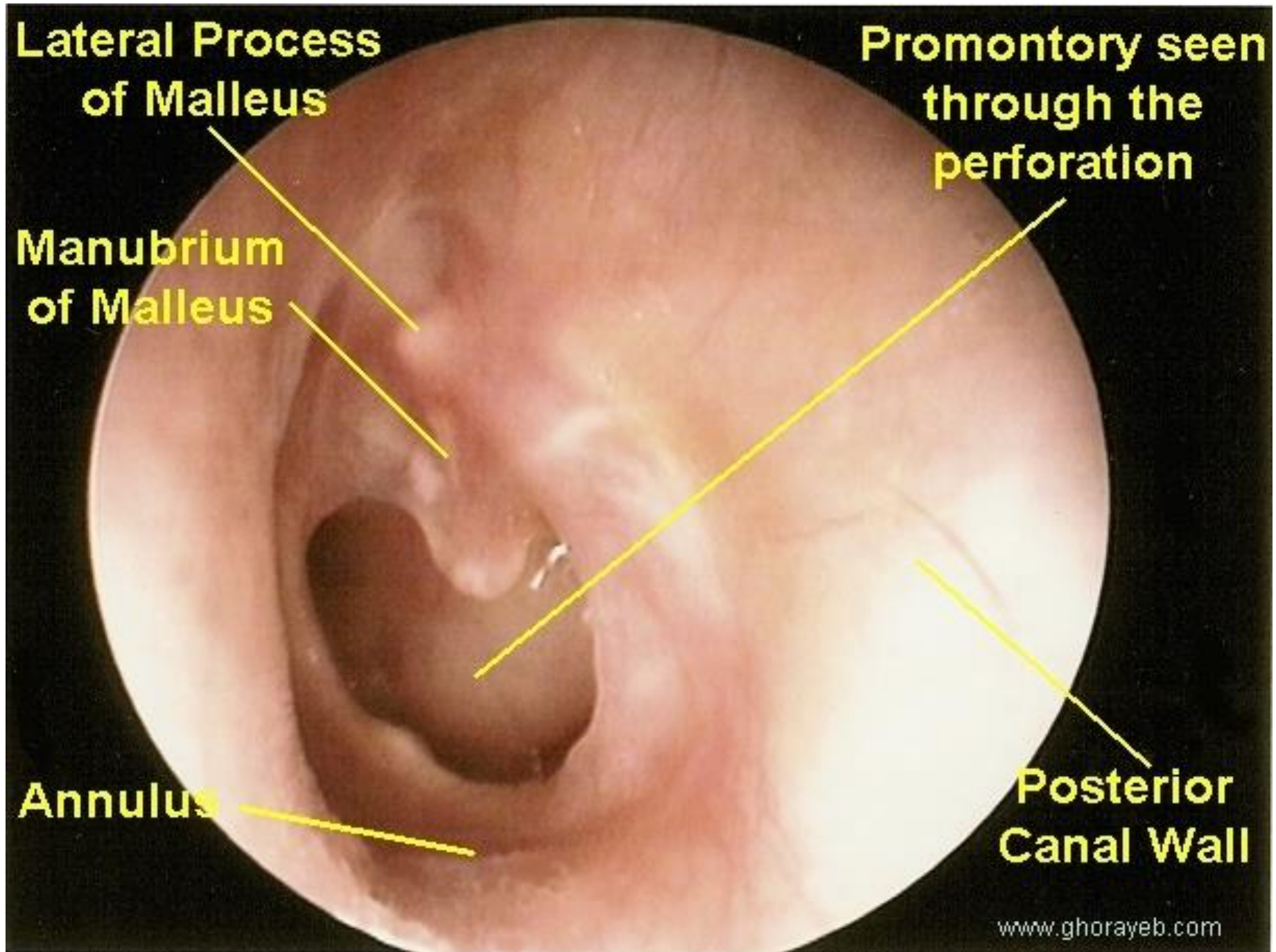
**Lateral Process
of Malleus**

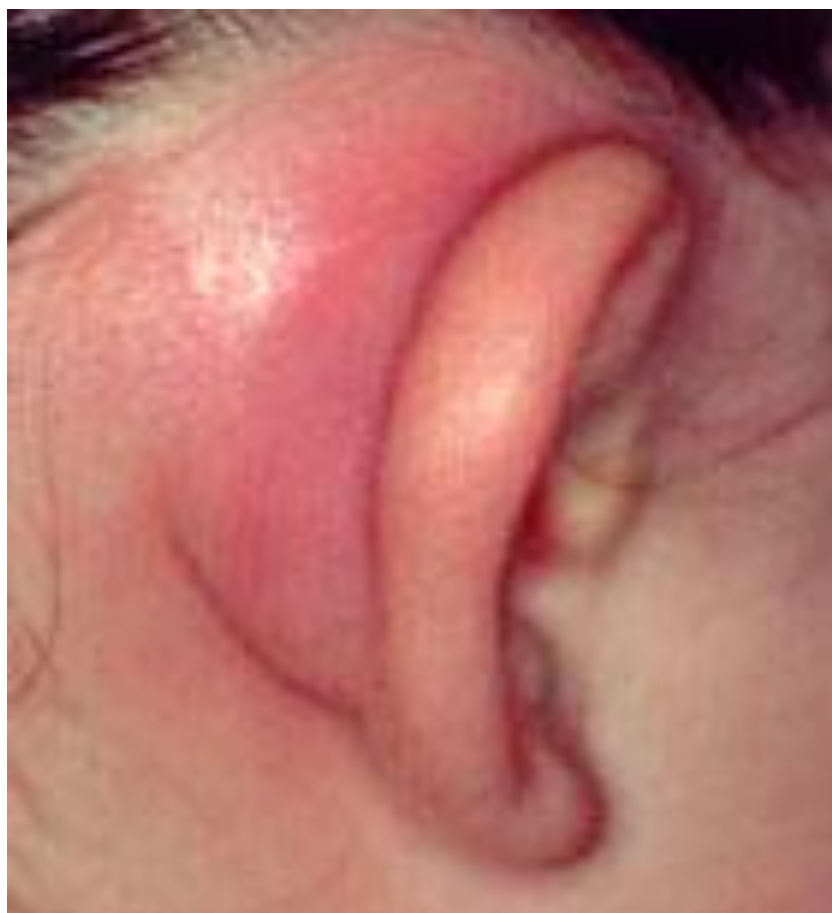**Promontory seen
through the
perforation**

**Manubrium
of Malleus**

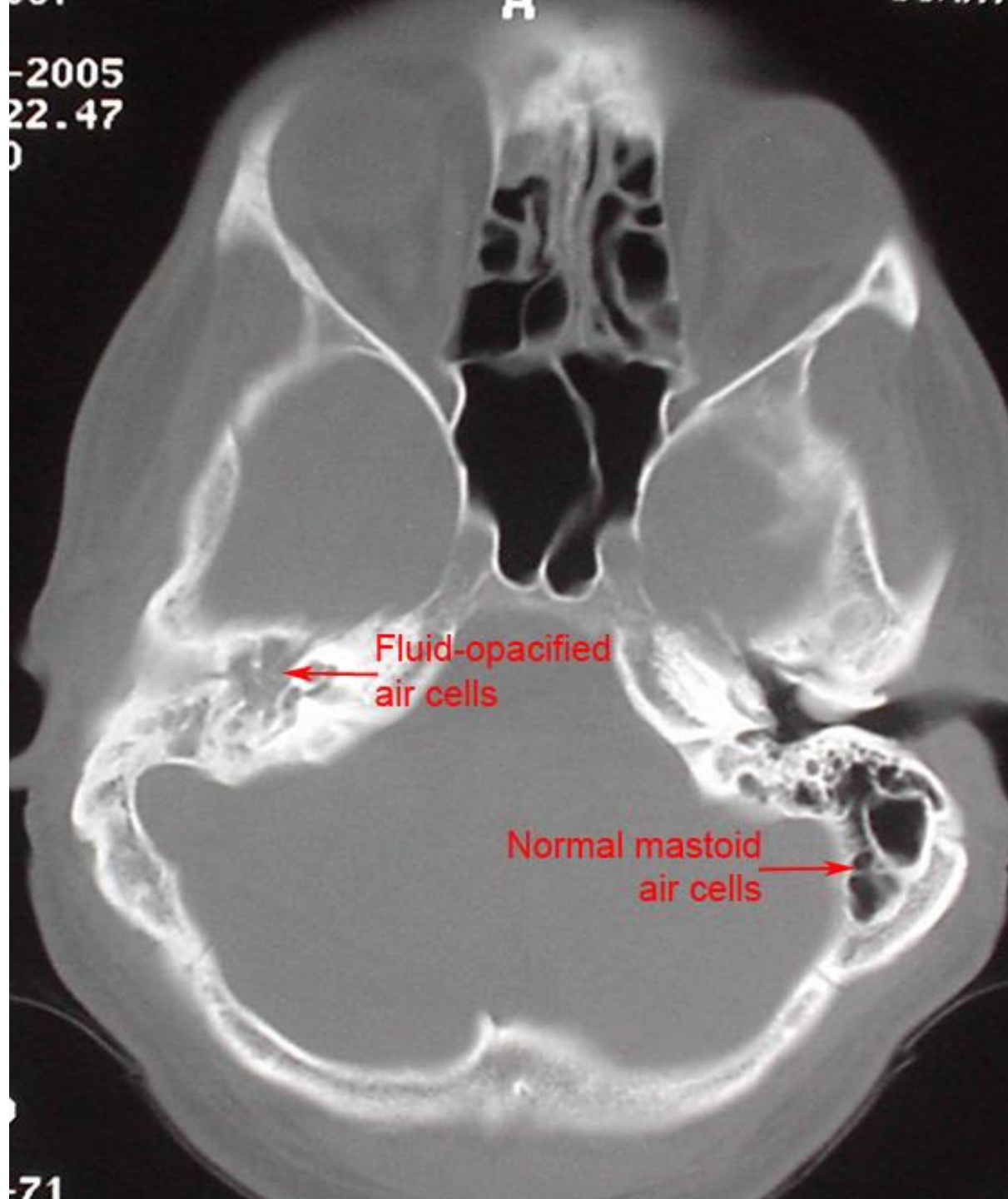
Annulus

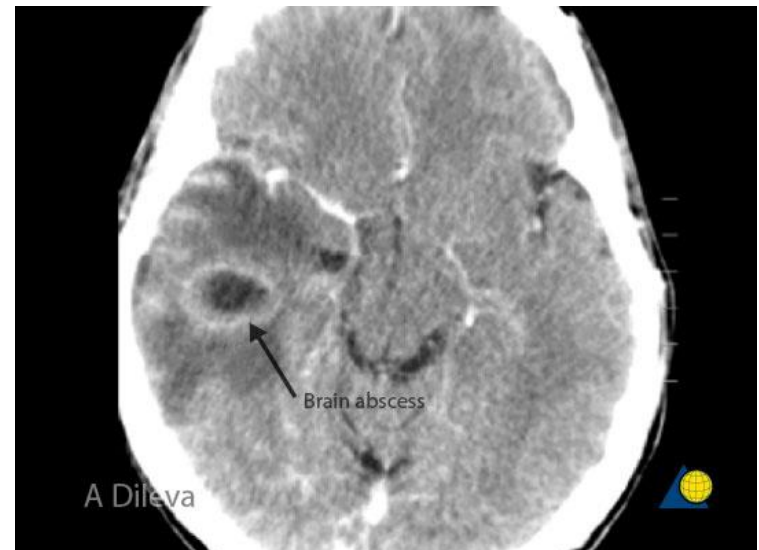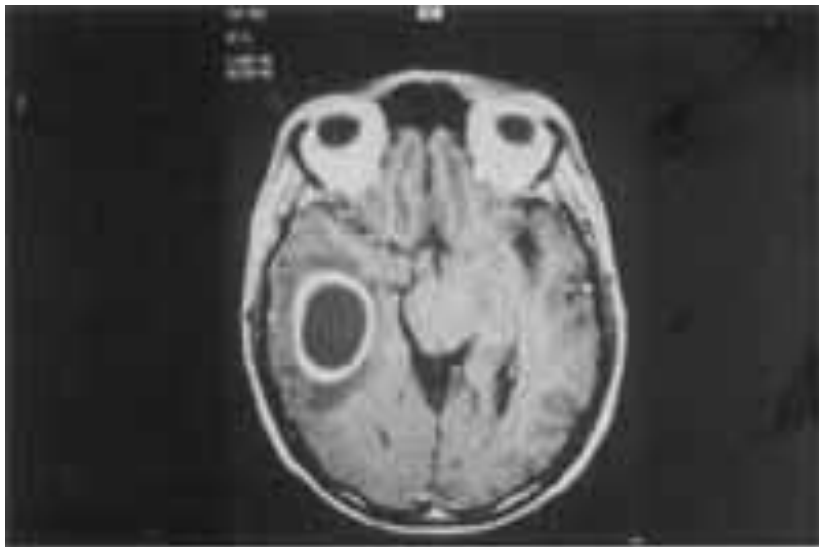
**Posterior
Canal Wall**

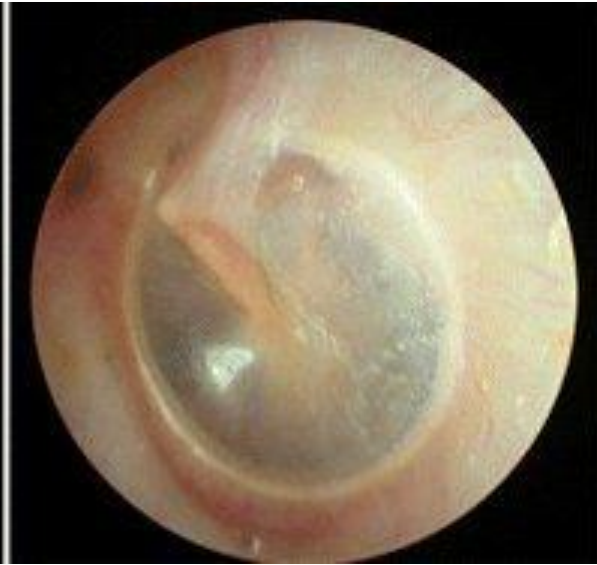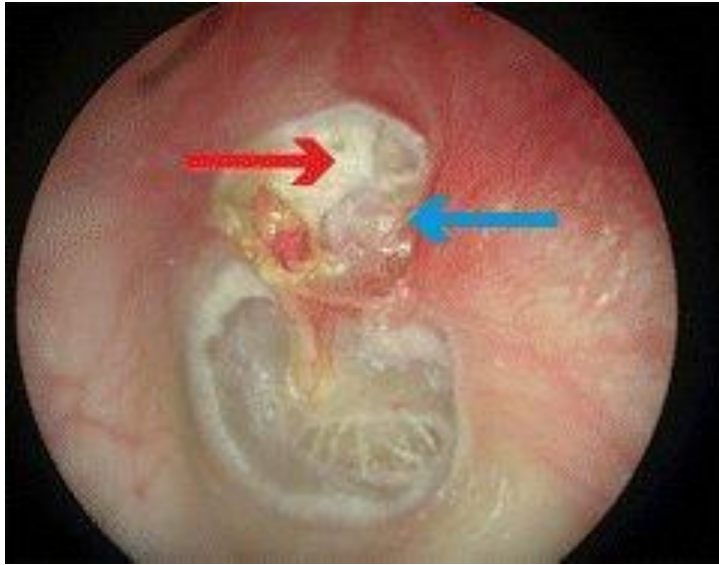


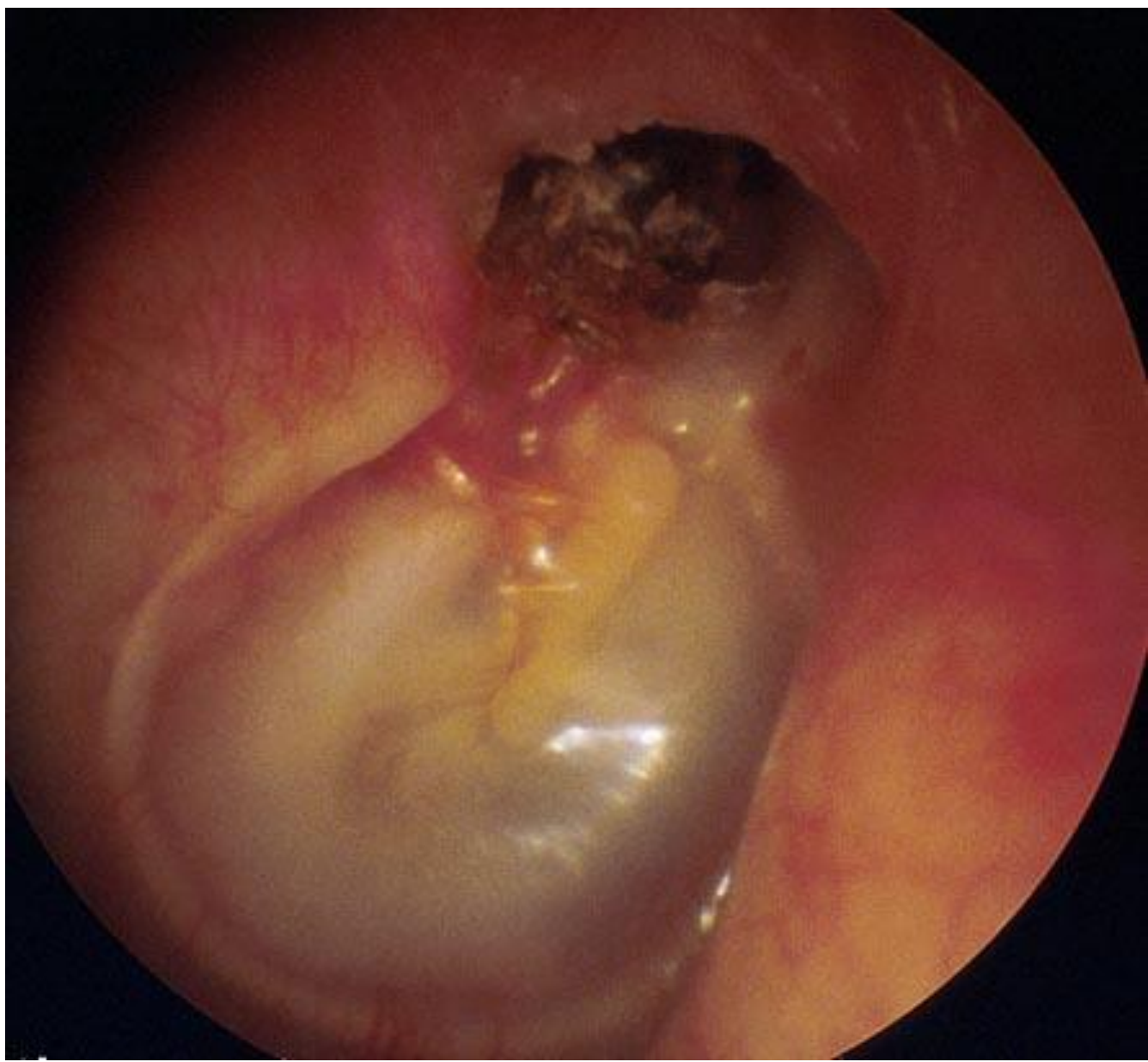


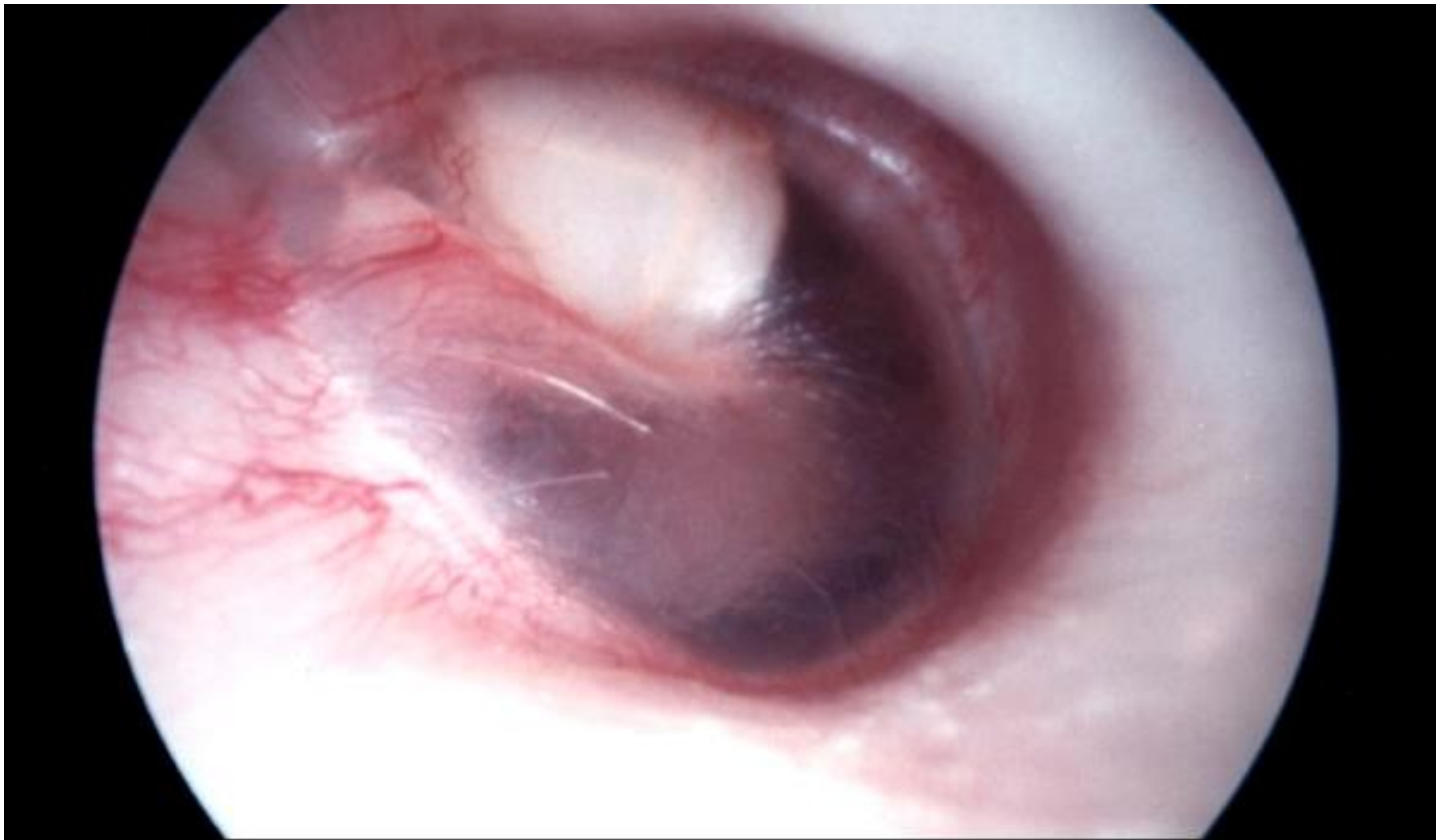
2005
22.47
0











Congenital Cholesteatoma

Aural Polyp

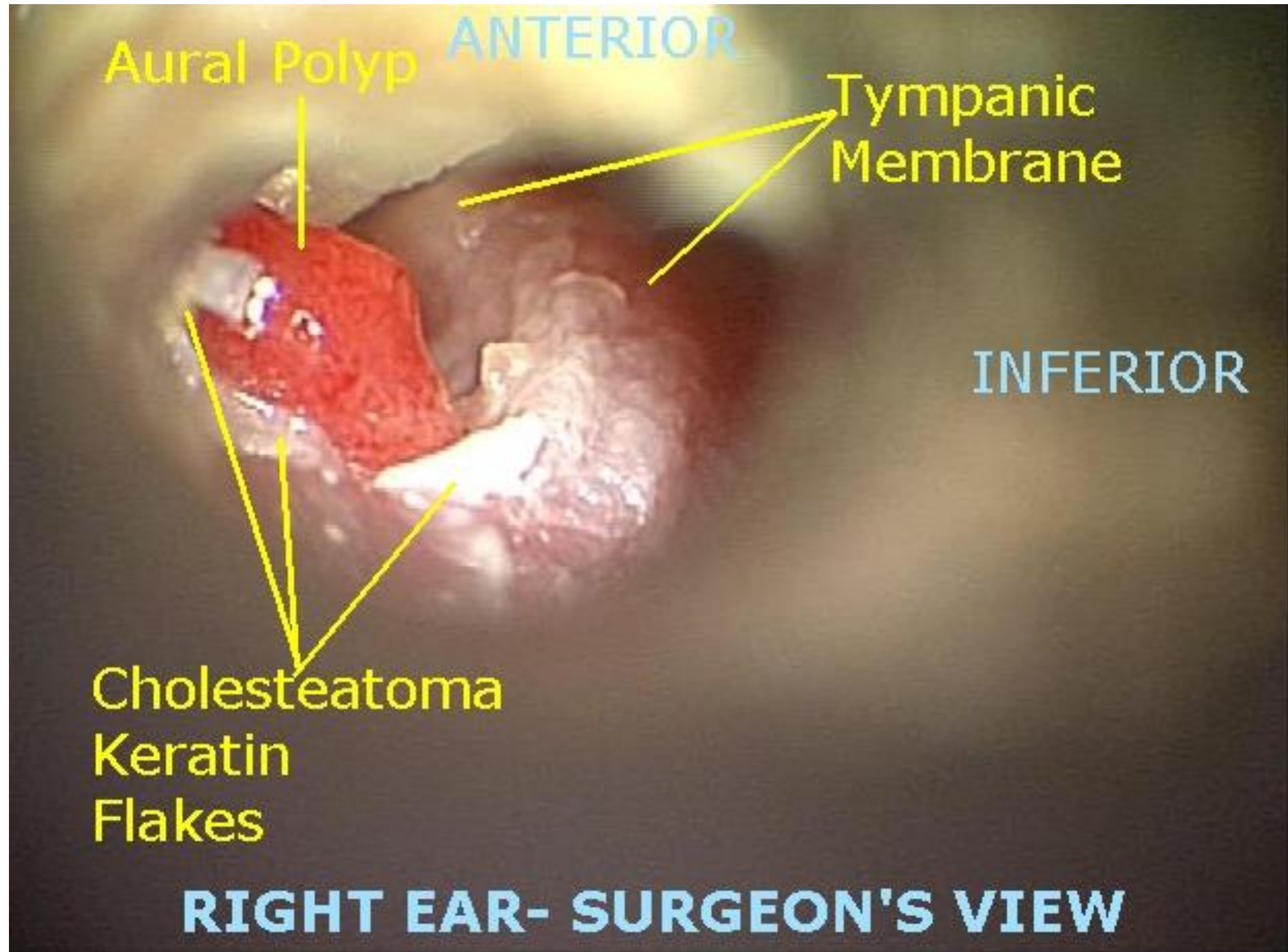
ANTERIOR

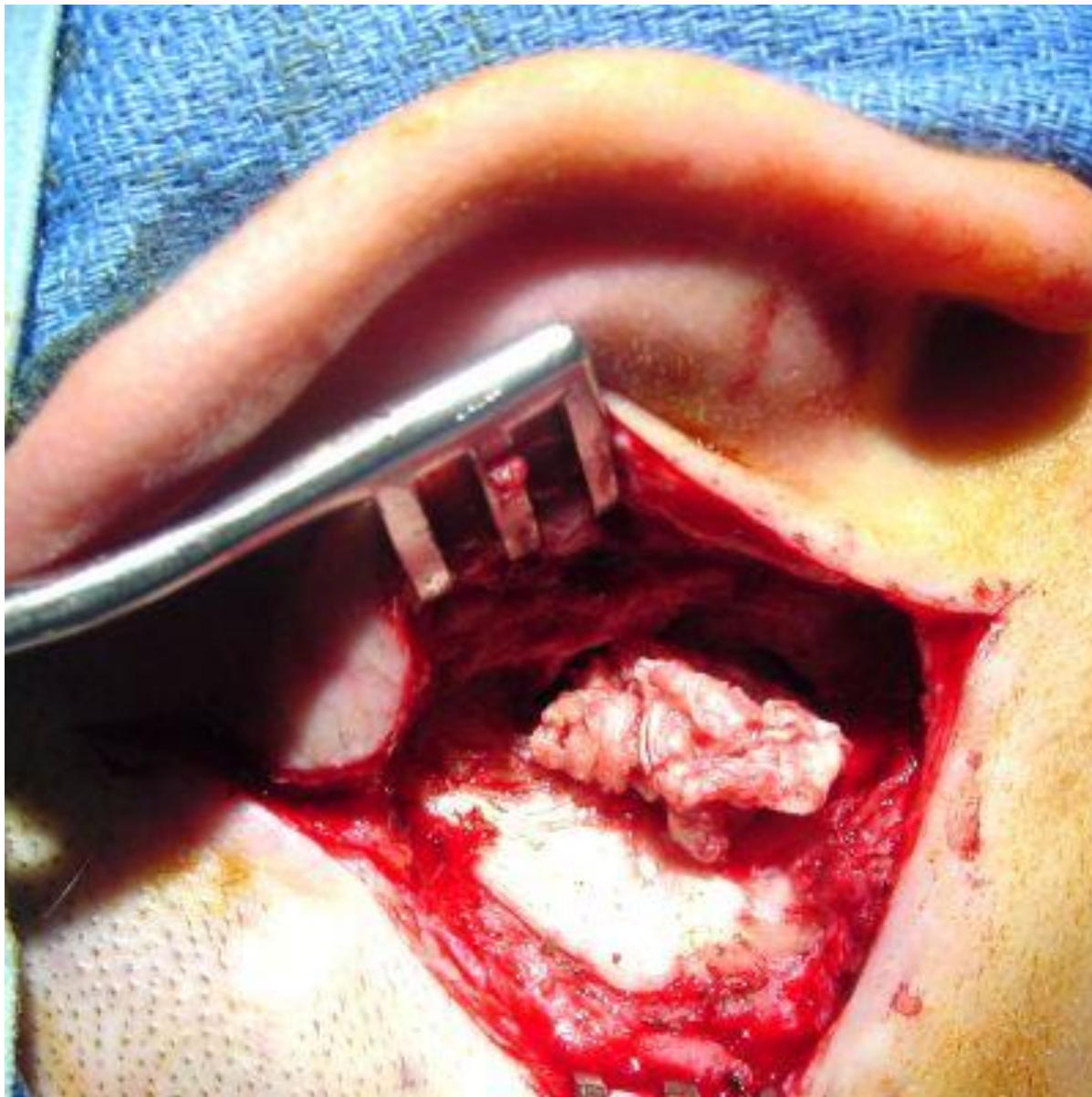
Tympanic
Membrane

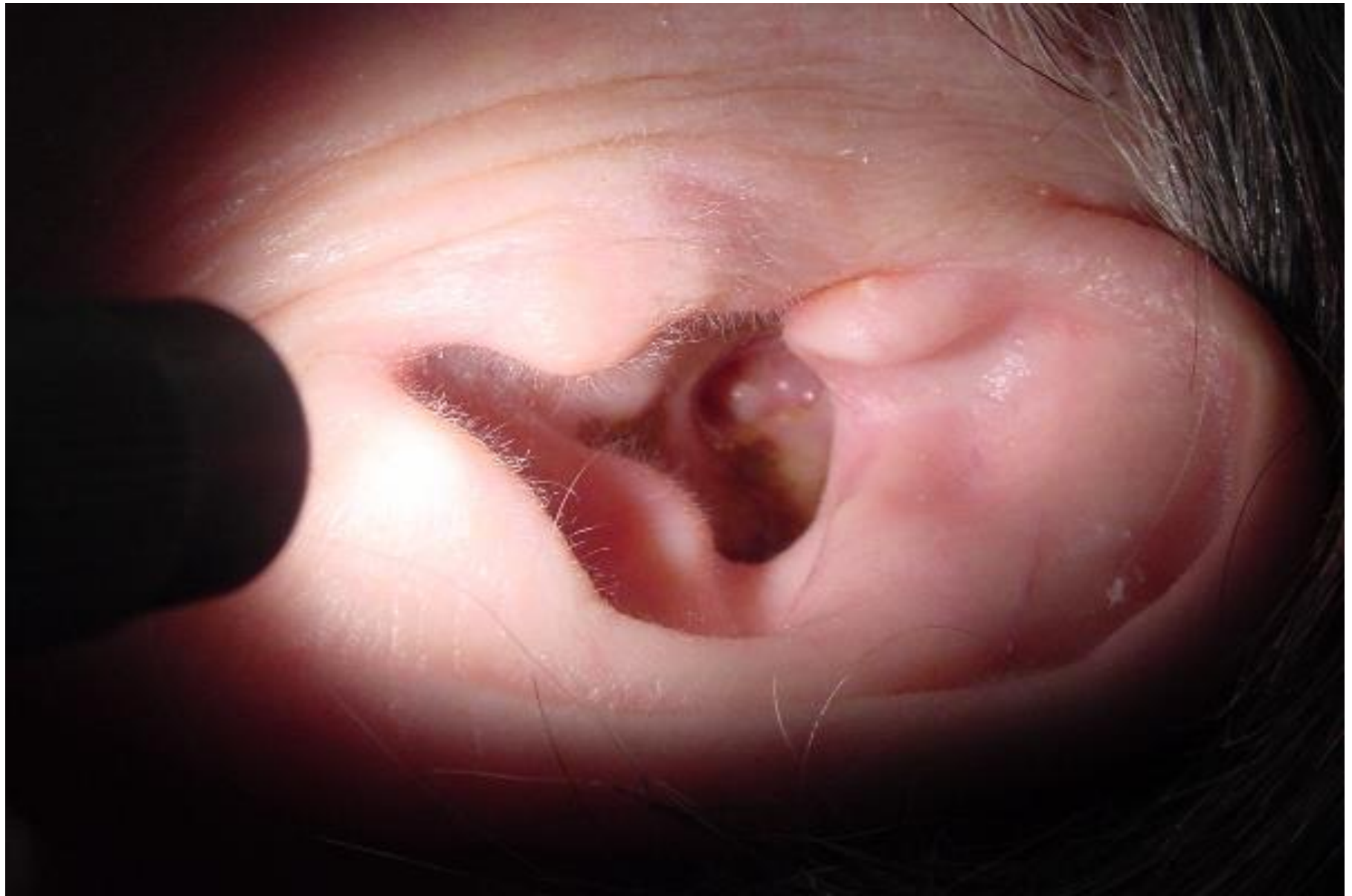INFERIOR

Cholesteatoma
Keratin
Flakes

RIGHT EAR- SURGEON'S VIEW



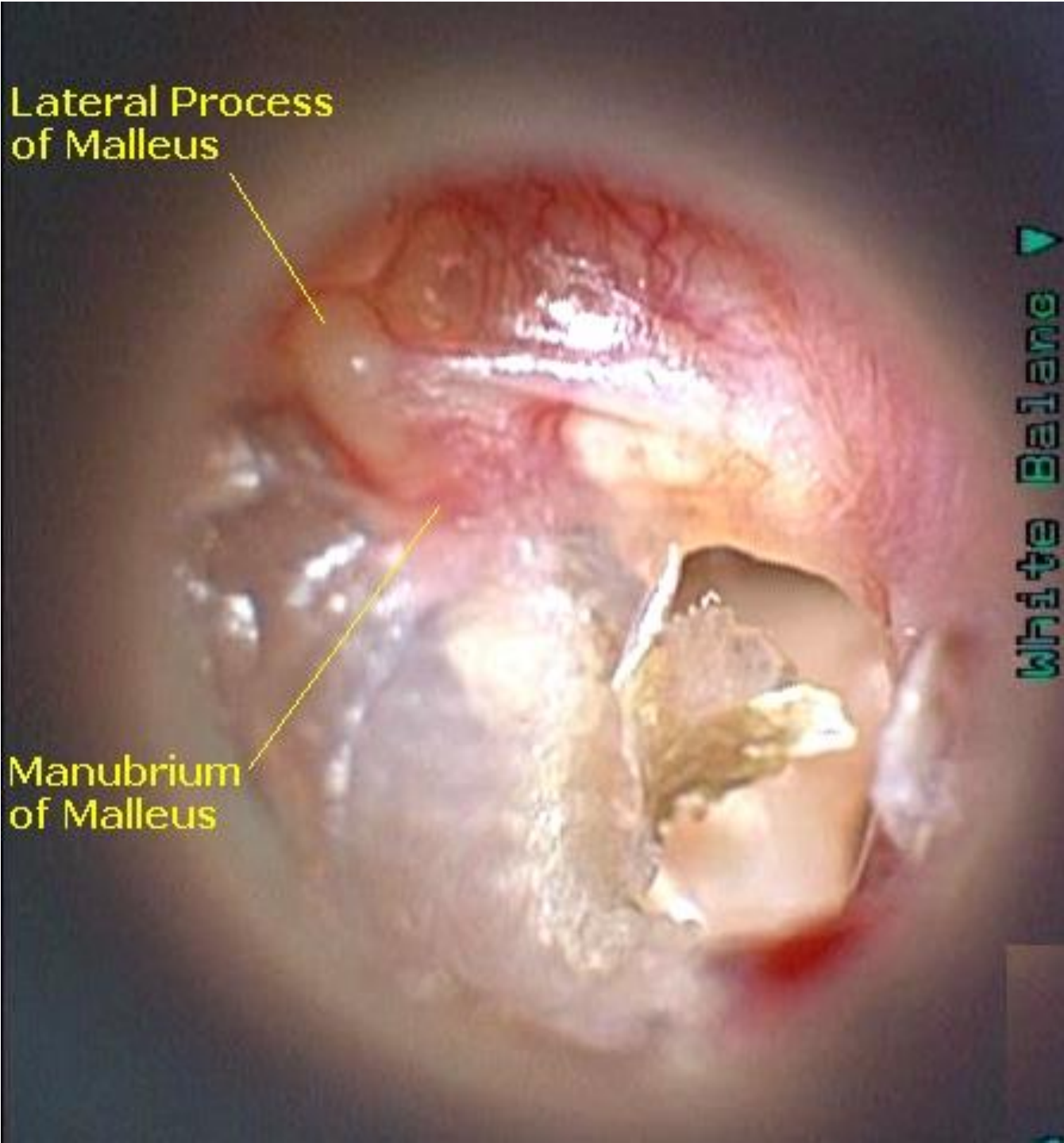


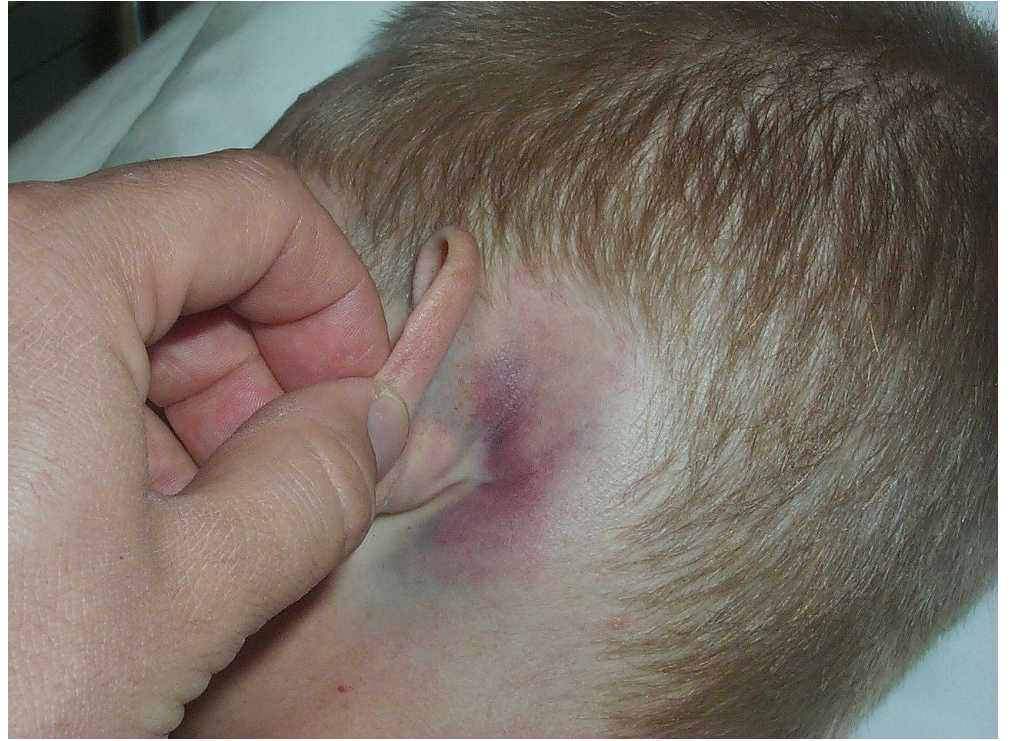
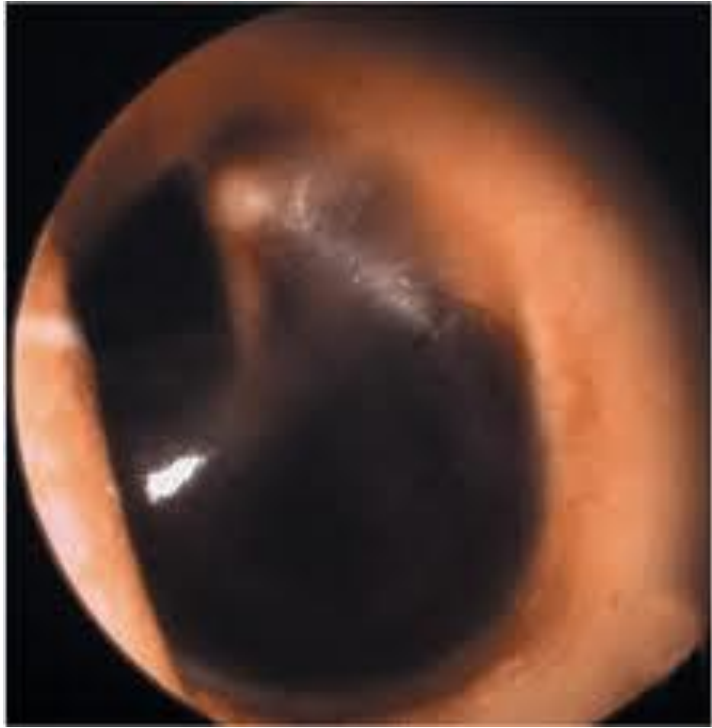
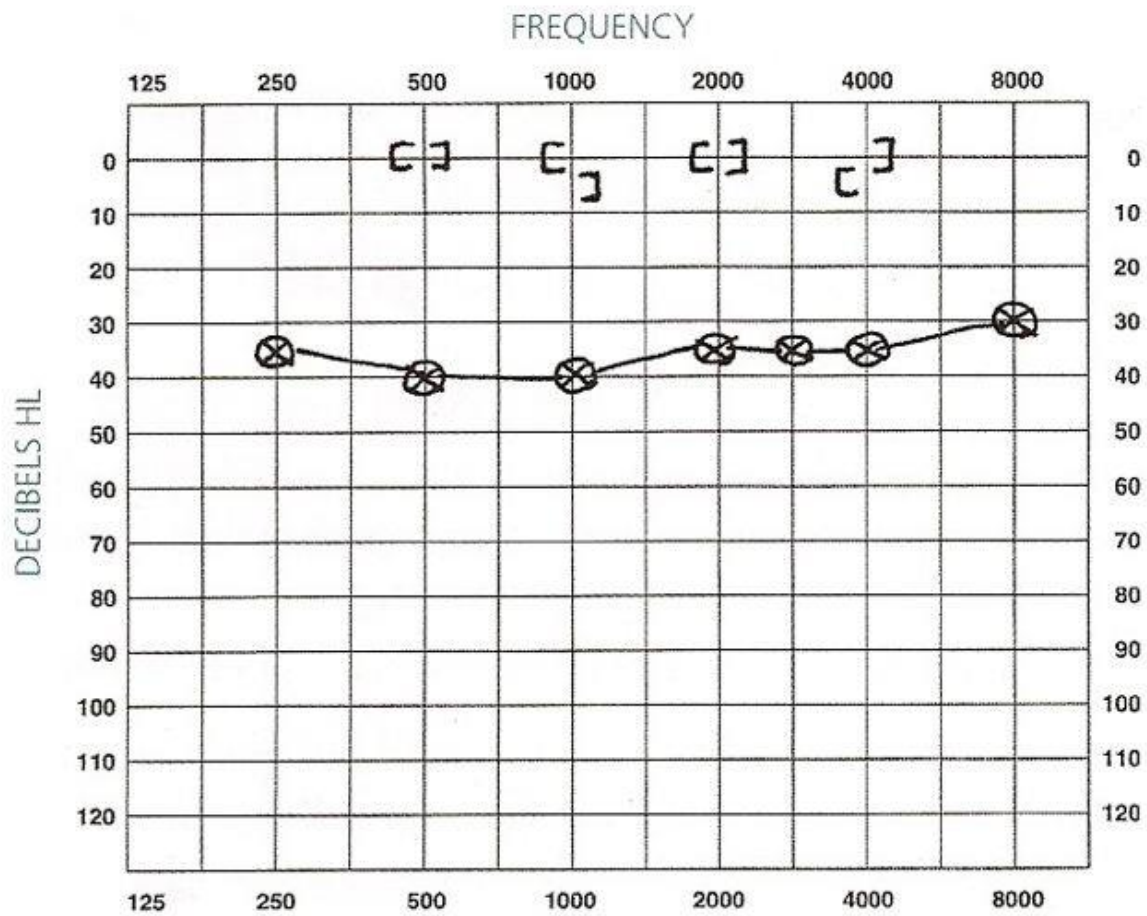
Lateral Process
of Malleus

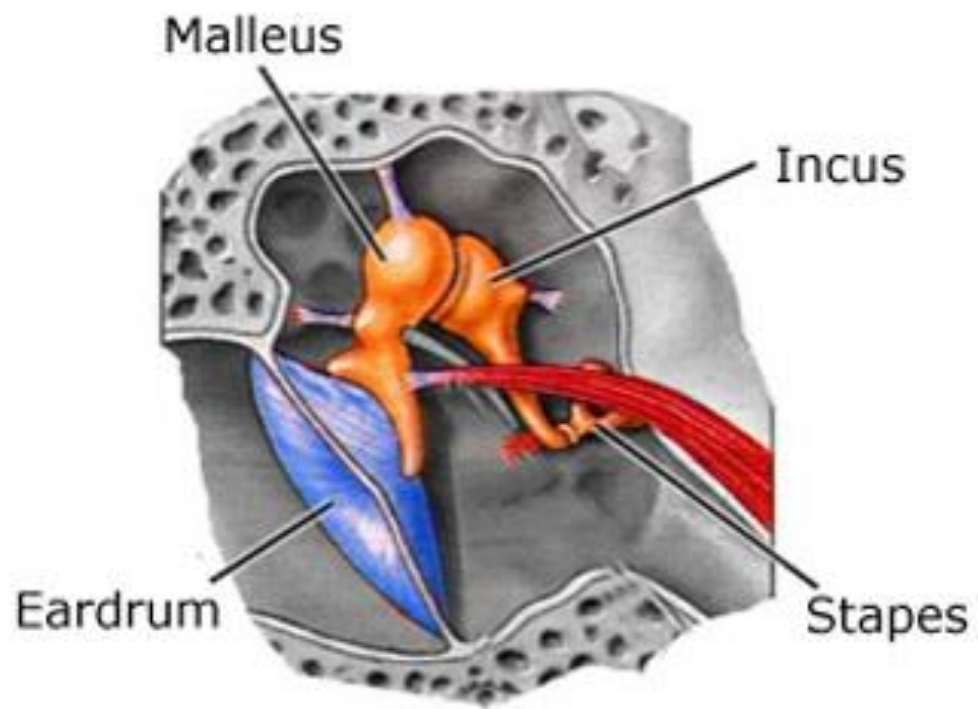
Manubrium
of Malleus

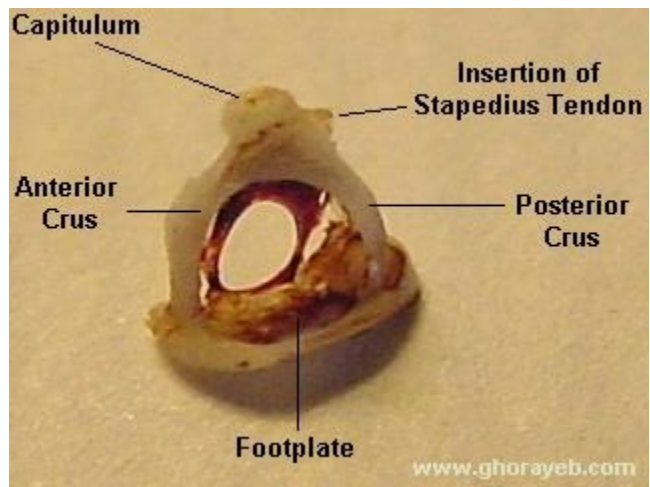
White Balance ▽

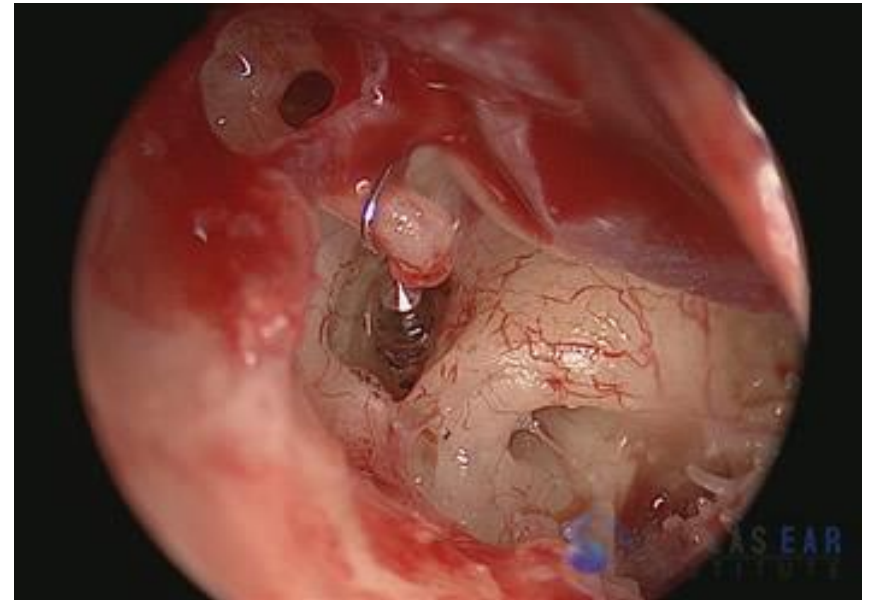
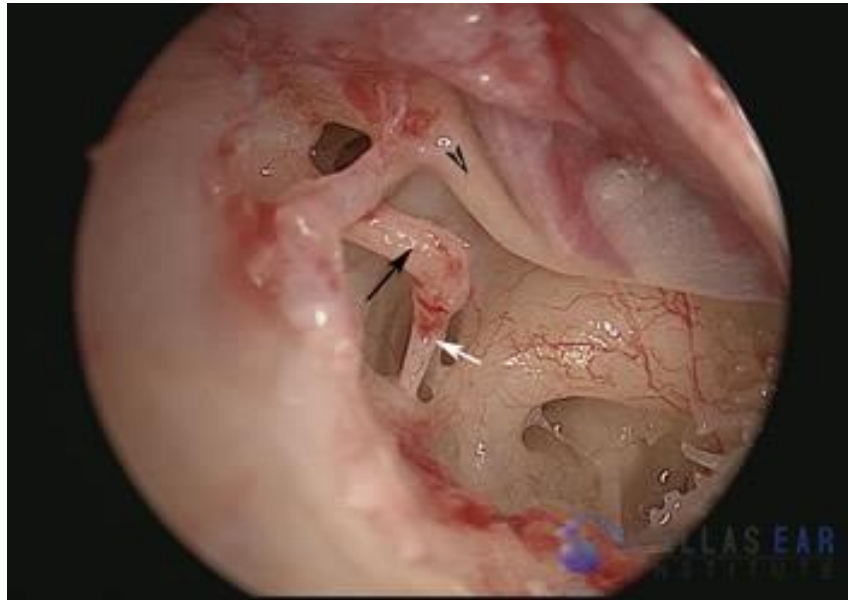


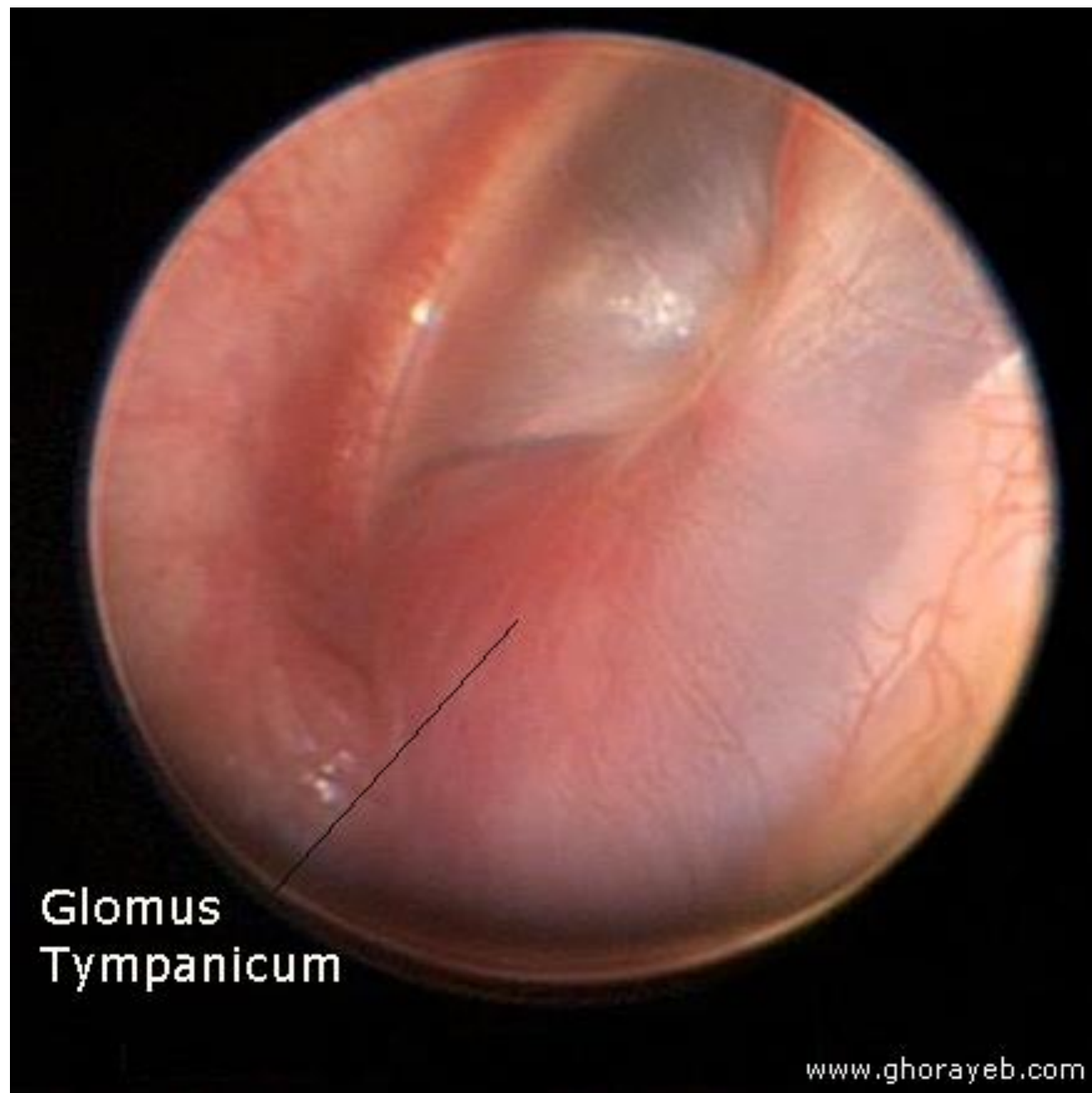




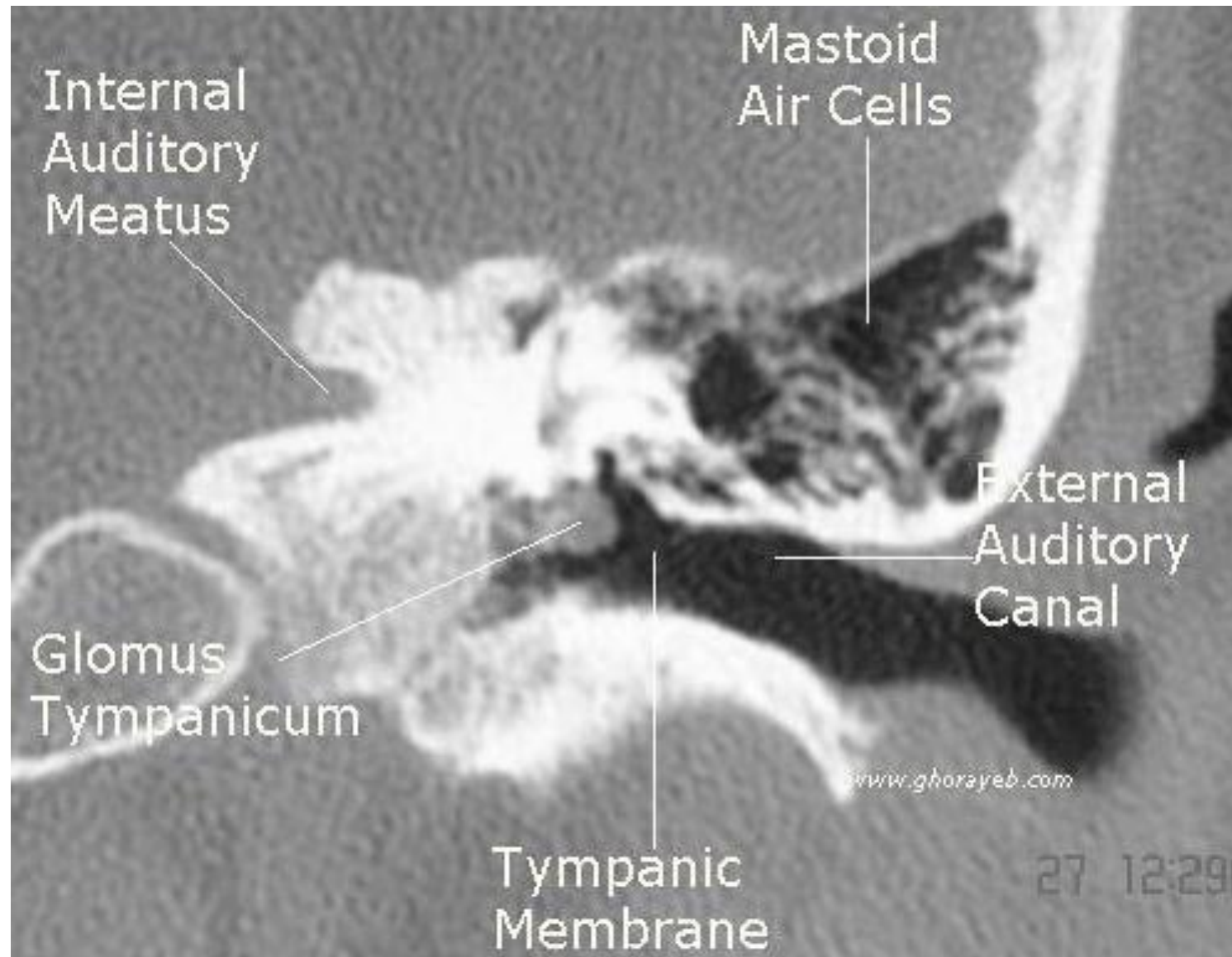








Glomus
Tympanicum

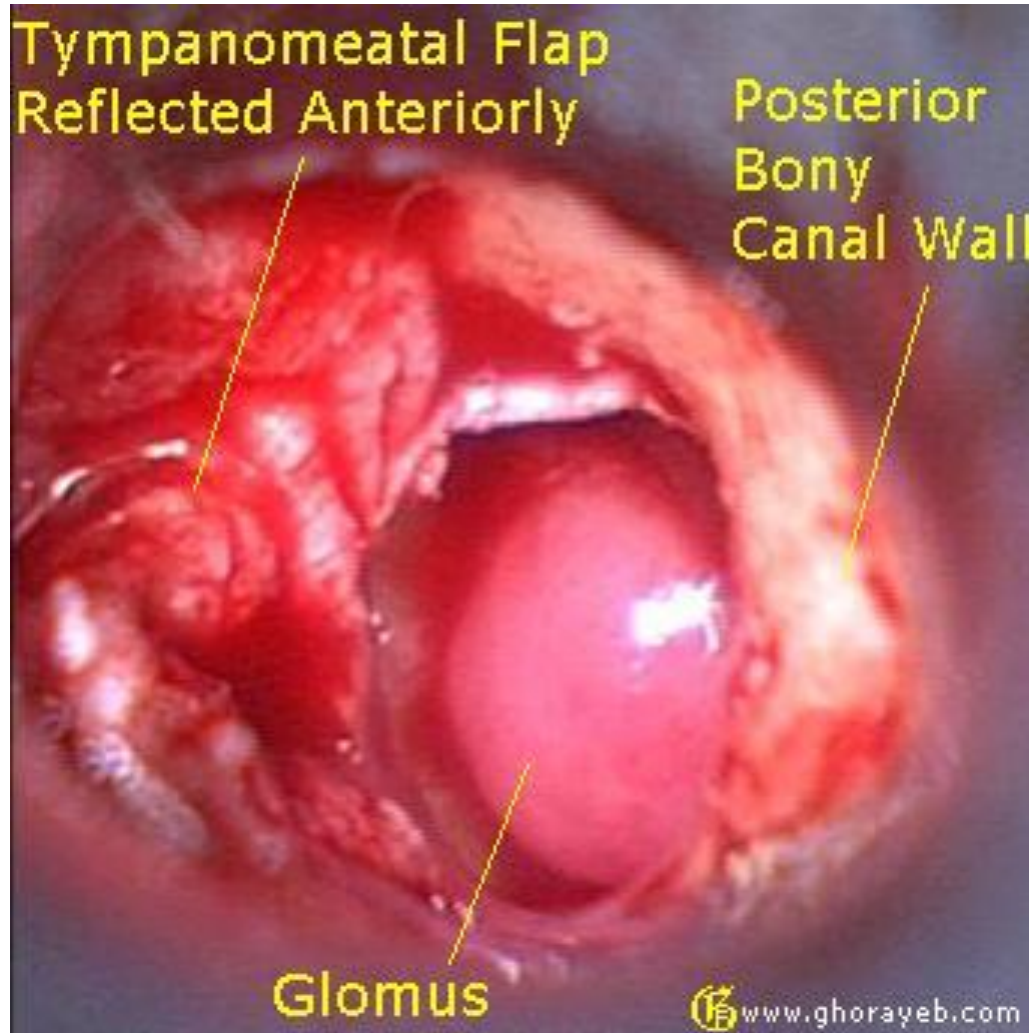


Tympanomeatal Flap
Reflected Anteriorly

Posterior
Bony
Canal Wall

Glomus

 www.ghorayeb.com



Tympanomeatal Flap Raised

Glomus Tympanicum

Annulus

Posterior Bony Canal Wall



Video ▼

www.ghorayeb.com